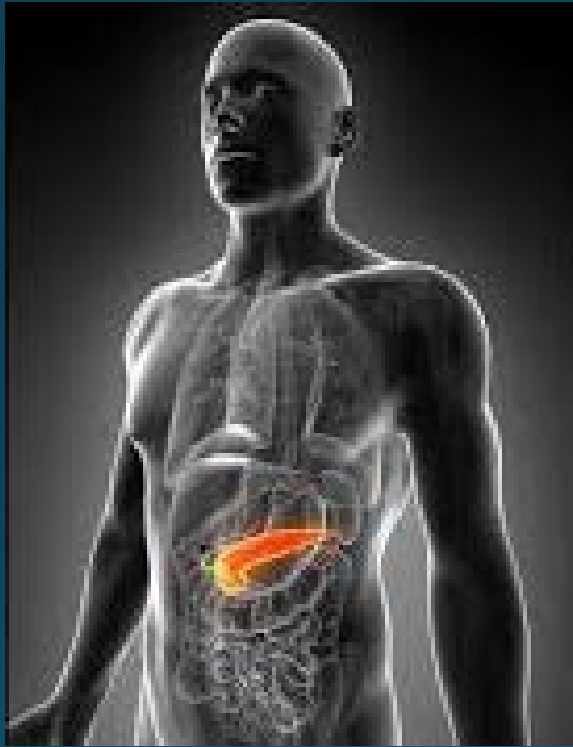




Case 4

Hossein Taghizadeh

Clinical Oncology
Medical University of Vienna



Medical History

- 50 year old male, bank employee and business man
 - Patient from Romania
 - Married, 1 daughter
 - Parents both alive
 - Never smoked, drinks rarely
 - No comorbidities, fit, ECOG 0
 - 175cm, 69 kg
- 
- A close-up, low-angle shot of a person's hand typing on a laptop keyboard. The lighting is dramatic, with the hand and keyboard in shadow against a bright, out-of-focus background. The text is overlaid on the left side of the image.

Medical History

- Patient diagnosed with metastatic PDAC in Romania
- Patient already received 5x cycles systemic chemotherapy with FOLFIRINOX in Romania; CA 19-9 1500
- Patient wanted to continue systemic chemotherapy in Vienna

Diagnose: N.pancreatis met (hep., V.a. ossär) histologisch verifiziert

St.p. 5 Cy FOLFOXIRI

In der letzten CT zeigt sich zumindest eine Stable Disease; V.a. ossäre SBL

Procedere:

1. ad TB (30.10.)

2. MRT der BWS

3. Fortführung der Therapie mit FOLFIRINOX für 3 weitere Zyklen

Pat. hat nunmehr eine E-Card und möchte seine Therapie am AKH-Wien fortführen.

PRODIGE 4/ACCORD 11 phase III trial

The NEW ENGLAND JOURNAL of MEDICINE

ORIGINAL ARTICLE

FOLFIRINOX versus Gemcitabine for Metastatic Pancreatic Cancer

Thierry Conroy, M.D., Françoise Desseigne, M.D., Marc Ychou, M.D., Ph.D.,
Olivier Bouché, M.D., Ph.D., Rosine Guimbaud, M.D., Ph.D.,
Yves Bécouarn, M.D., Antoine Adenis, M.D., Ph.D., Jean-Luc Raoul, M.D., Ph.D.,
Sophie Gourgou-Bourgade, M.Sc., Christelle de la Fouchardière, M.D.,
Jaafar Bennouna, M.D., Ph.D., Jean-Baptiste Bachet, M.D.,
Faiza Khemissa-Akouz, M.D., Denis Péré-Vergé, M.D., Catherine Delbaldo, M.D.,
Eric Assenat, M.D., Ph.D., Bruno Chauffert, M.D., Ph.D., Pierre Michel, M.D., Ph.D.,
Christine Montoto-Grillot, M.Chem., and Michel Ducreux, M.D., Ph.D.,
for the Groupe Tumeurs Digestives of Unicancer and the PRODIGE Intergroup*

Palliative chemotherapy

- Patient received further 3x cycles FOLFIRINOX
- →CT scan revealed Progressive disease of liver metastases

How would you proceed?

1. Observation/ Watchful waiting
2. Surgical Resection
3. Continue Palliative FOLFIRINOX
4. Palliative 5-fluorouracil/folinic acid
5. Palliative gemcitabine + capecitabine
6. Palliative gemcitabine + nab-Paclitaxel

Palliative chemotherapy

- Patient received further 3x cycles FOLFIRINOX
- →CT scan revealed Progressive disease of liver metastases
- Therapy change to gemcitabine and nab-paclitaxel
Pat received 3xcycles gemcitabine and nab-paclitaxel

MPACT phase III trial in 1st line

The NEW ENGLAND JOURNAL of MEDICINE

ORIGINAL ARTICLE

Increased Survival in Pancreatic Cancer with nab-Paclitaxel plus Gemcitabine

Daniel D. Von Hoff, M.D., Thomas Ervin, M.D., Francis P. Arena, M.D.,
E. Gabriela Chiorean, M.D., Jeffrey Infante, M.D., Malcolm Moore, M.D.,
Thomas Seay, M.D., Sergei A. Tjulandin, M.D., Wen Wee Ma, M.D.,
Mansoor N. Saleh, M.D., Marion Harris, M.D., Michele Reni, M.D.,
Scot Dowden, M.D., Daniel Laheru, M.D., Nathan Bahary, M.D.,
Ramesh K. Ramanathan, M.D., Josep Tabernero, M.D.,
Manuel Hidalgo, M.D., Ph.D., David Goldstein, M.D., Eric Van Cutsem, M.D.,
Xinyu Wei, Ph.D., Jose Iglesias, M.D., and Markus F. Renschler, M.D.

Palliative chemotherapy

- Patient received further 3x cycles FOLFIRINOX
- →CT scan revealed Progressive disease of liver metastases
- Therapy change to gemcitabine and nab-paclitaxel
Pat received 3xcycles gemcitabine and nab-paclitaxel
- →CT scan revealed Progressive disease of liver metastases
- Therapy change to Nanoliposomal Irinotecan + Fluorouracil + Folinic acid after failure of gemcitabine-based chemotherapy

NAPOLI-1 phase III trial

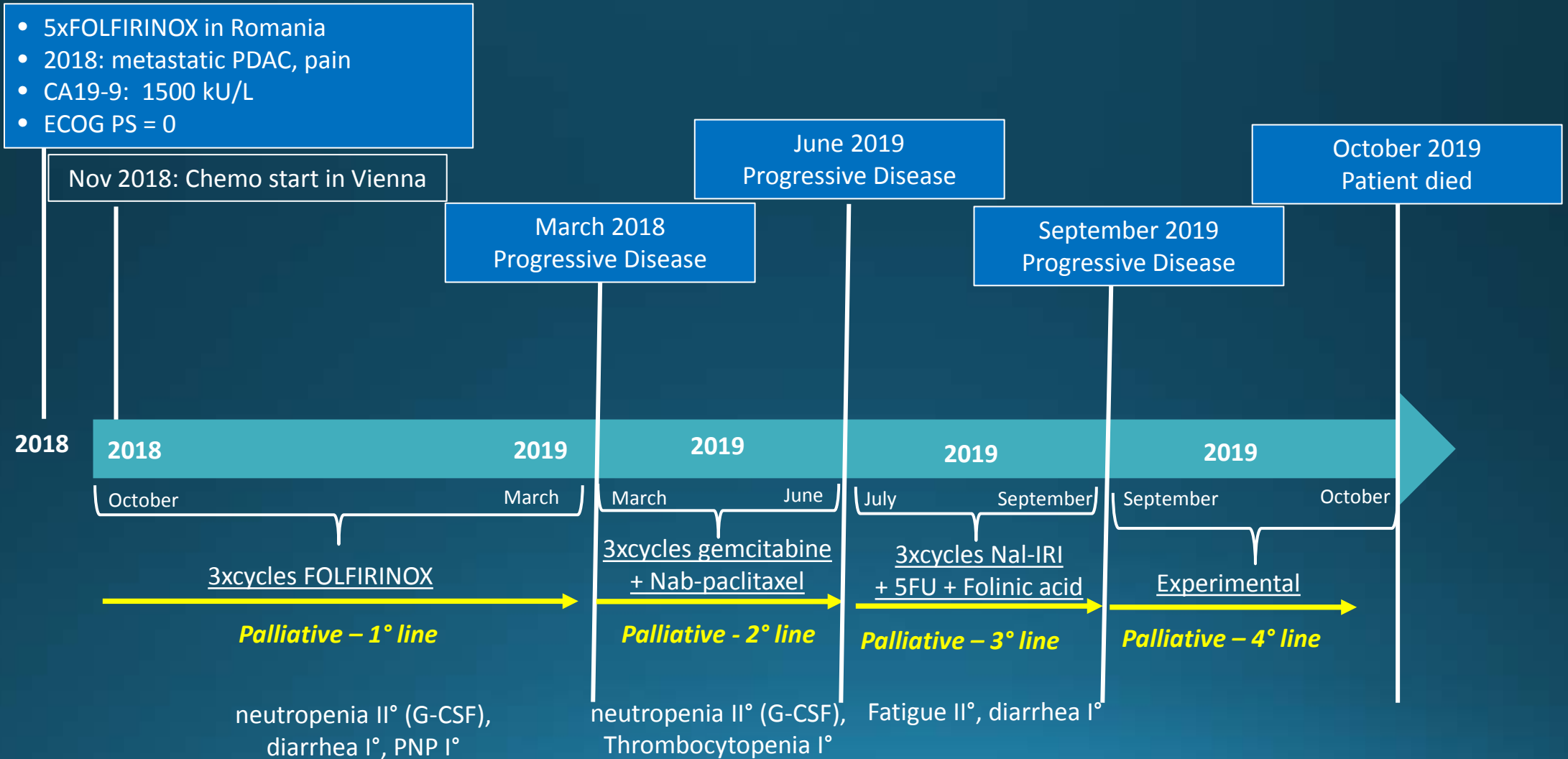
Nanoliposomal irinotecan with fluorouracil and folinic acid in metastatic pancreatic cancer after previous gemcitabine-based therapy (NAPOLI-1): a global, randomised, open-label, phase 3 trial

Andrea Wang-Gillam, Chung-Pin Li, György Bodoky, Andrew Dean, Yan-Shen Shan, Gayle Jameson, Teresa Macarulla, Kyung-Hun Lee, David Cunningham, Jean F Blanc, Richard A Hubner, Chang-Fang Chiu, Gilberto Schwartzmann, Jens T Siveke, Fadi Braiteh, Victor Moyo, Bruce Belanger, Navreet Dhindsa, Eliel Bayever, Daniel D Von Hoff*, Li-Tzong Chen*, for the NAPOLI-1 Study Group†*

Palliative chemotherapy

- Patient received further 3x cycles FOLFIRINOX
- →CT scan revealed Progressive disease of liver metastases
- Therapy change to gemcitabine and nab-paclitaxel
Pat received 3xcycles gemcitabine and nab-paclitaxel
- →CT scan revealed Progressive disease of liver metastases
- Therapy change to Nanoliposomal Irinotecan + Fluorouracil + Folinic acid after failure of gemcitabine-based chemotherapy
- →CT scan revealed Progressive disease of liver AND bone metastases
- Therapy change to experimental

Case 4 - Timeline



Summary of palliative treatments

- 1st line FOLFIRINOX based on ACCORD trial
- 2nd line Gemcitabine + Nab-paclitaxel
- 3rd line Nanoliposomal irinotecan + fluorouracil + folinic acid
- Experimental treatment

Thank you!